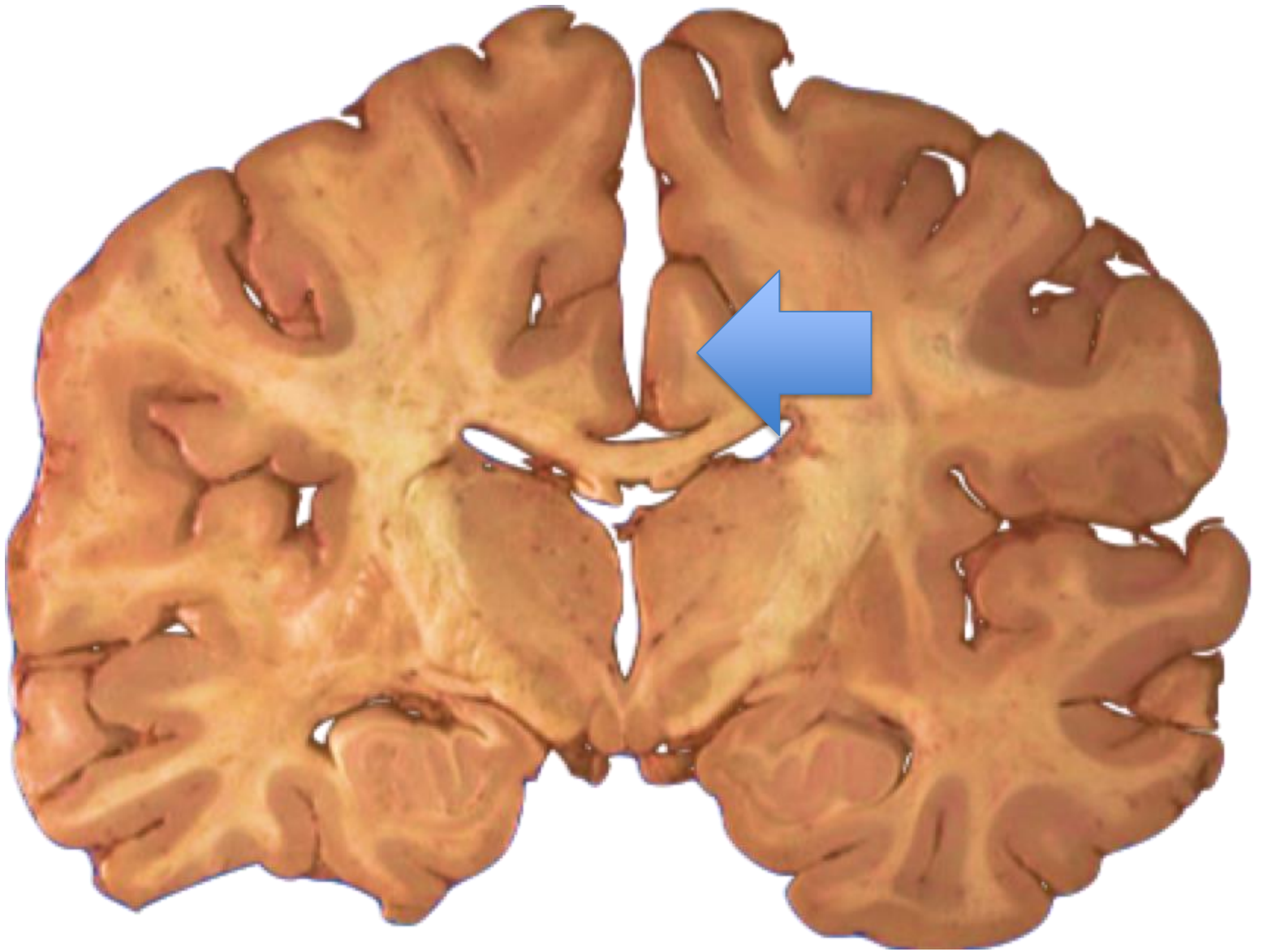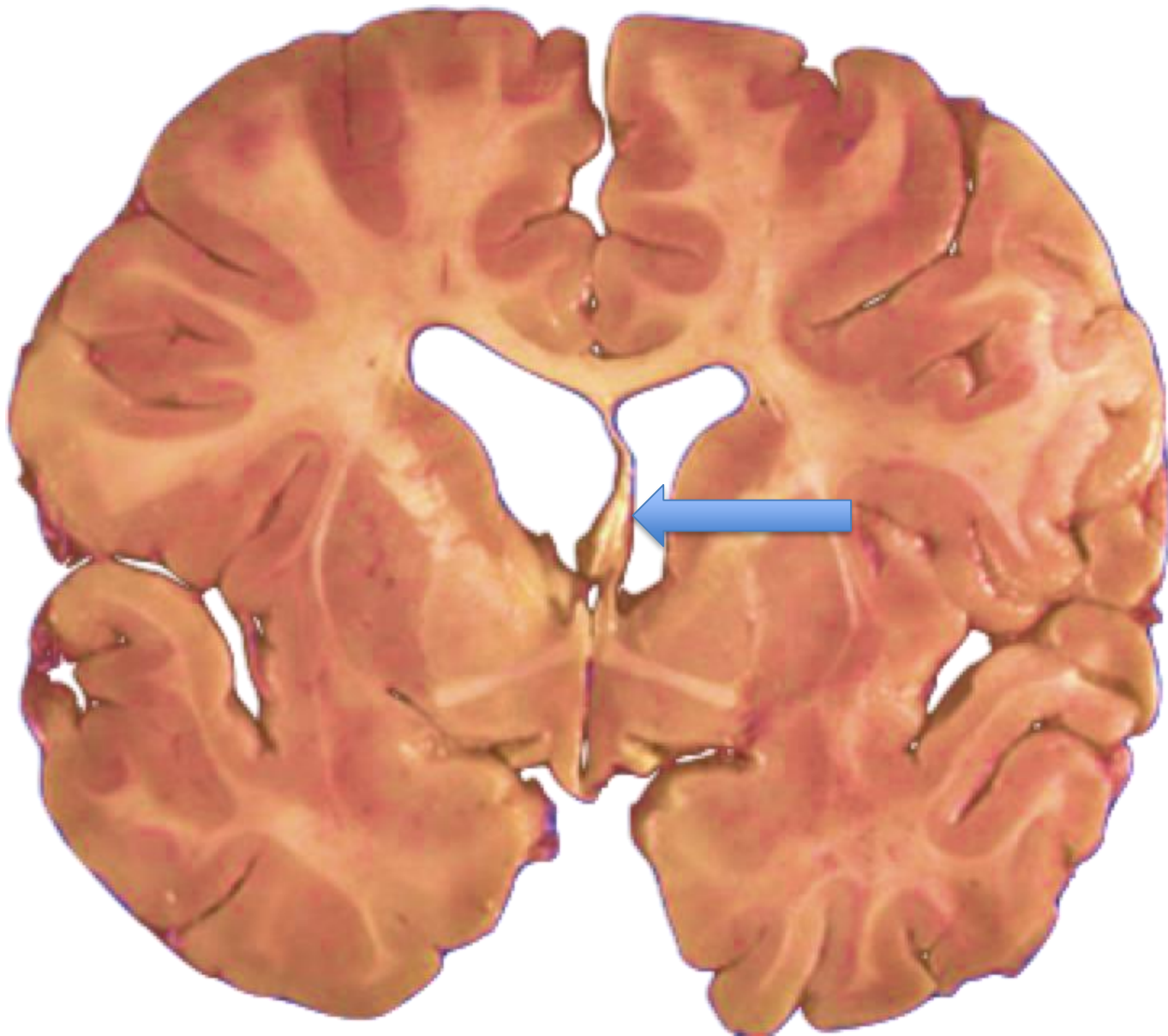
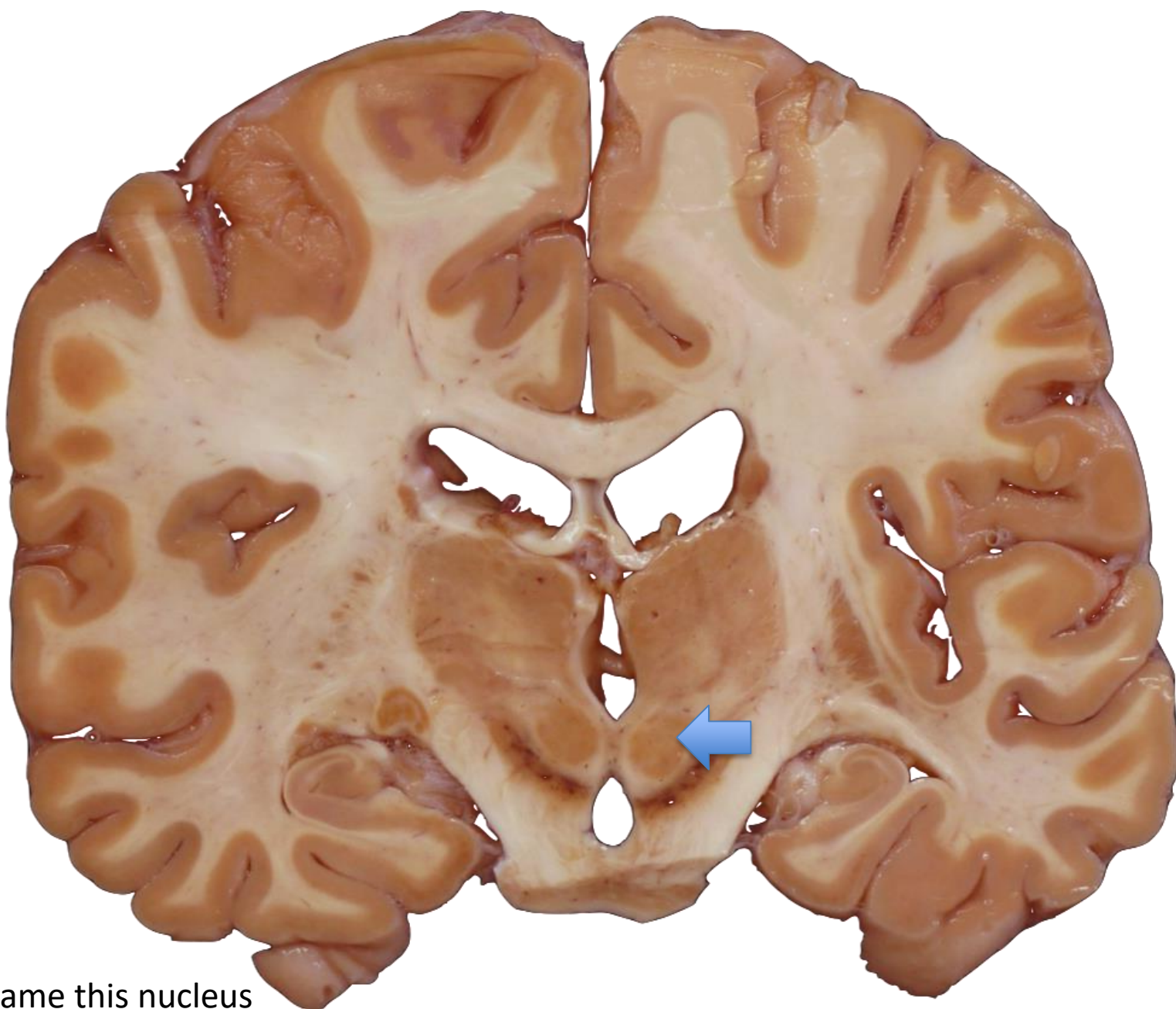


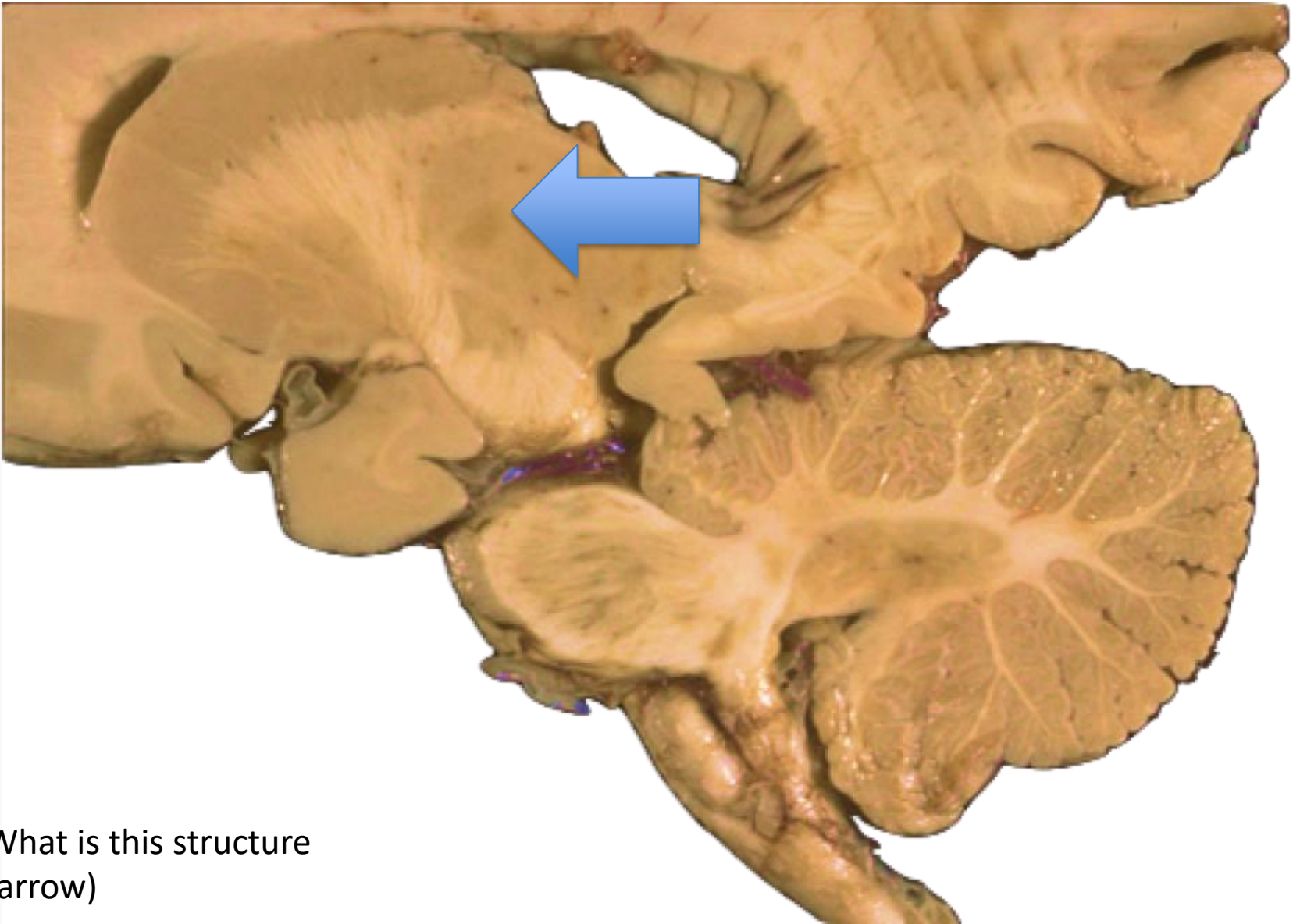
Name the gyrus
(Arrow)



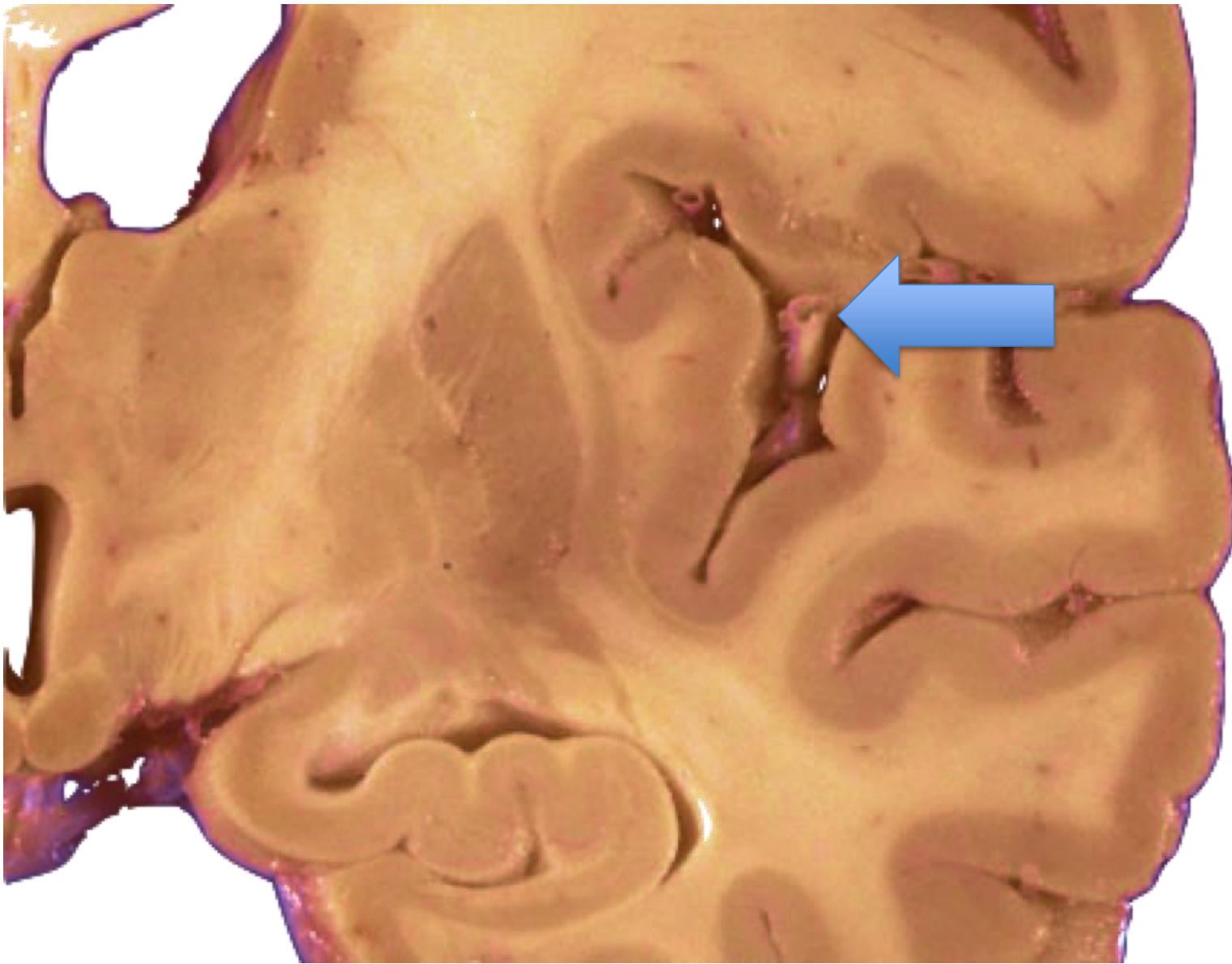
Name this structure (arrow)



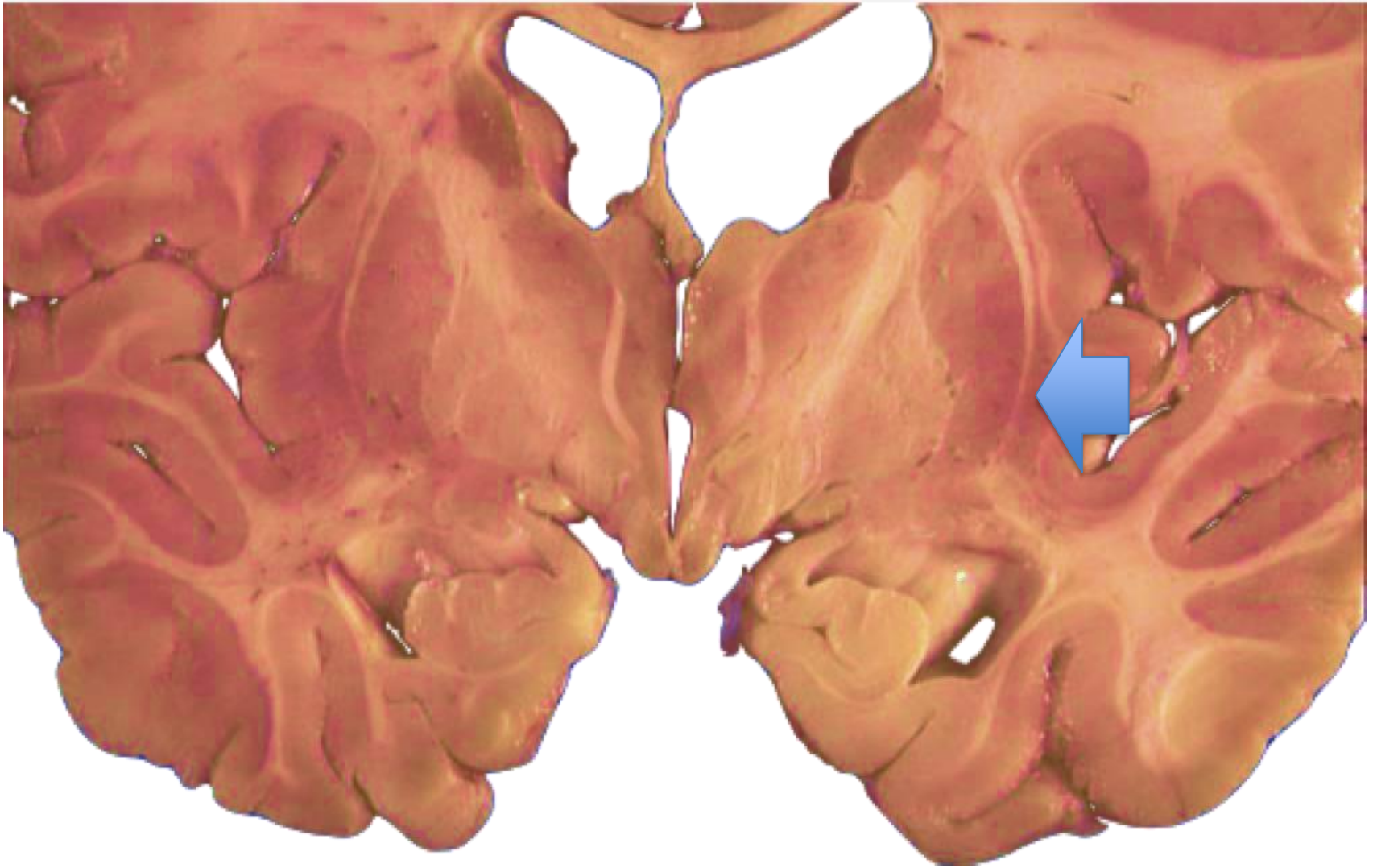
Name this nucleus
(Arrow)



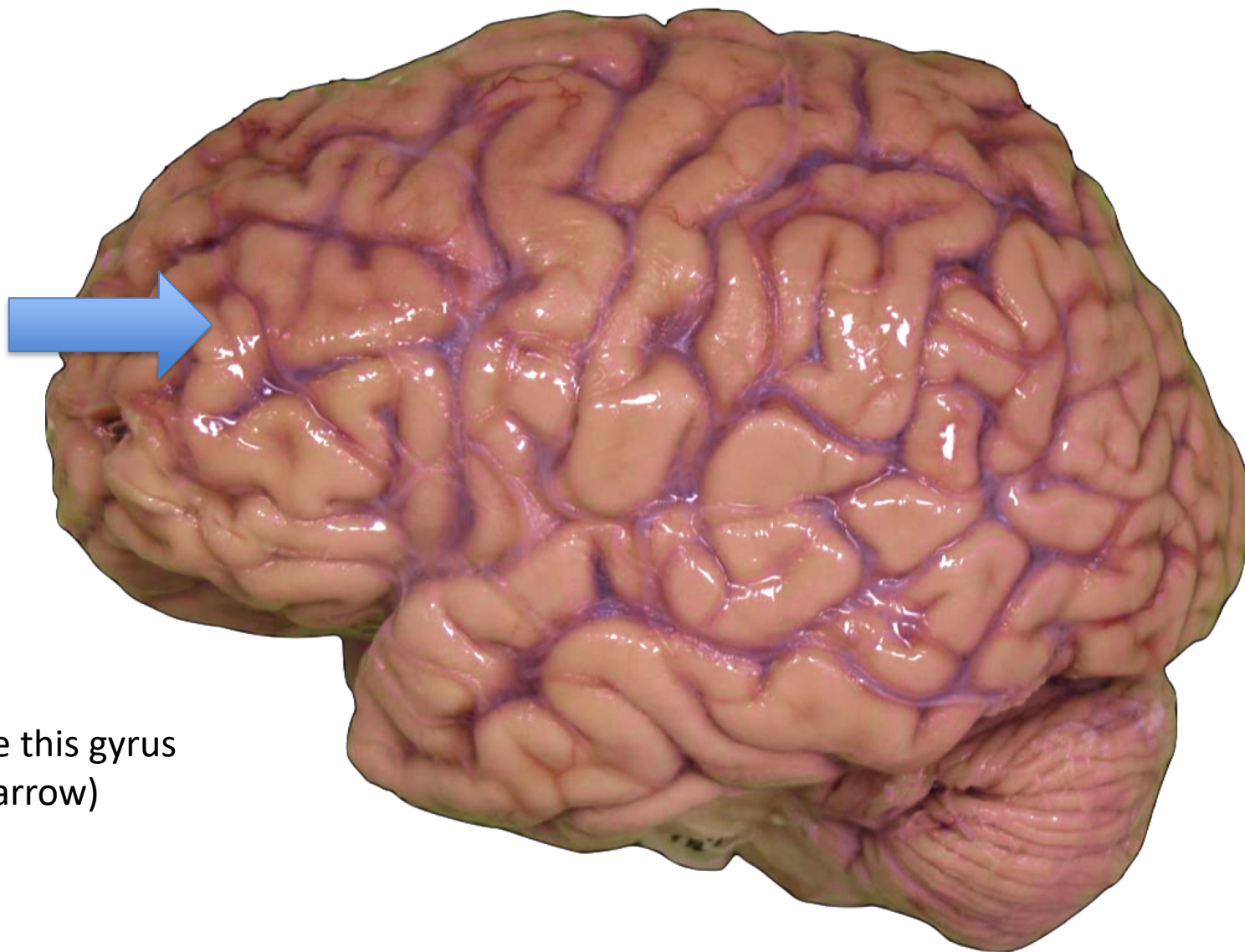
What is this structure
(arrow)



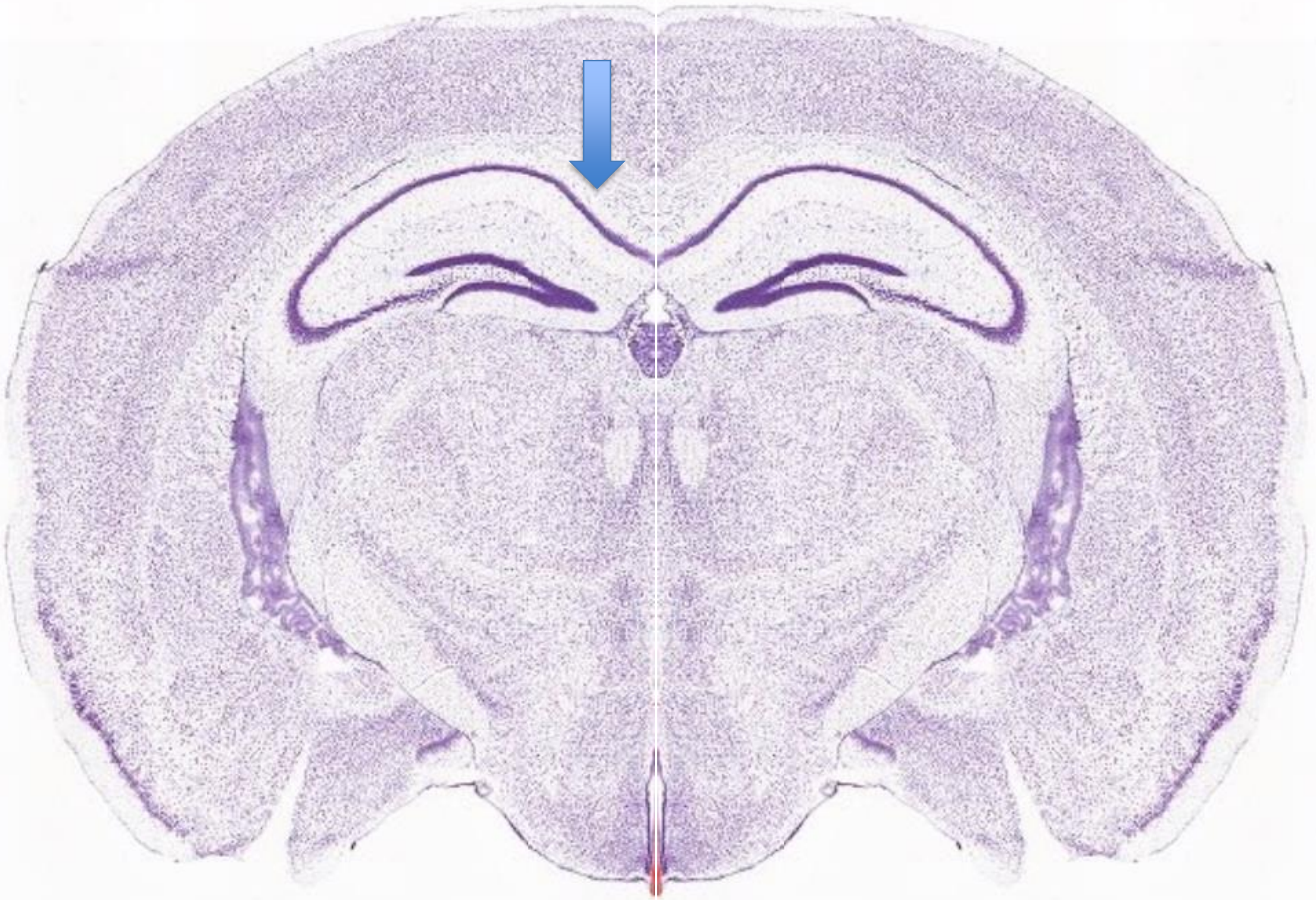Name this artery
(Arrow)



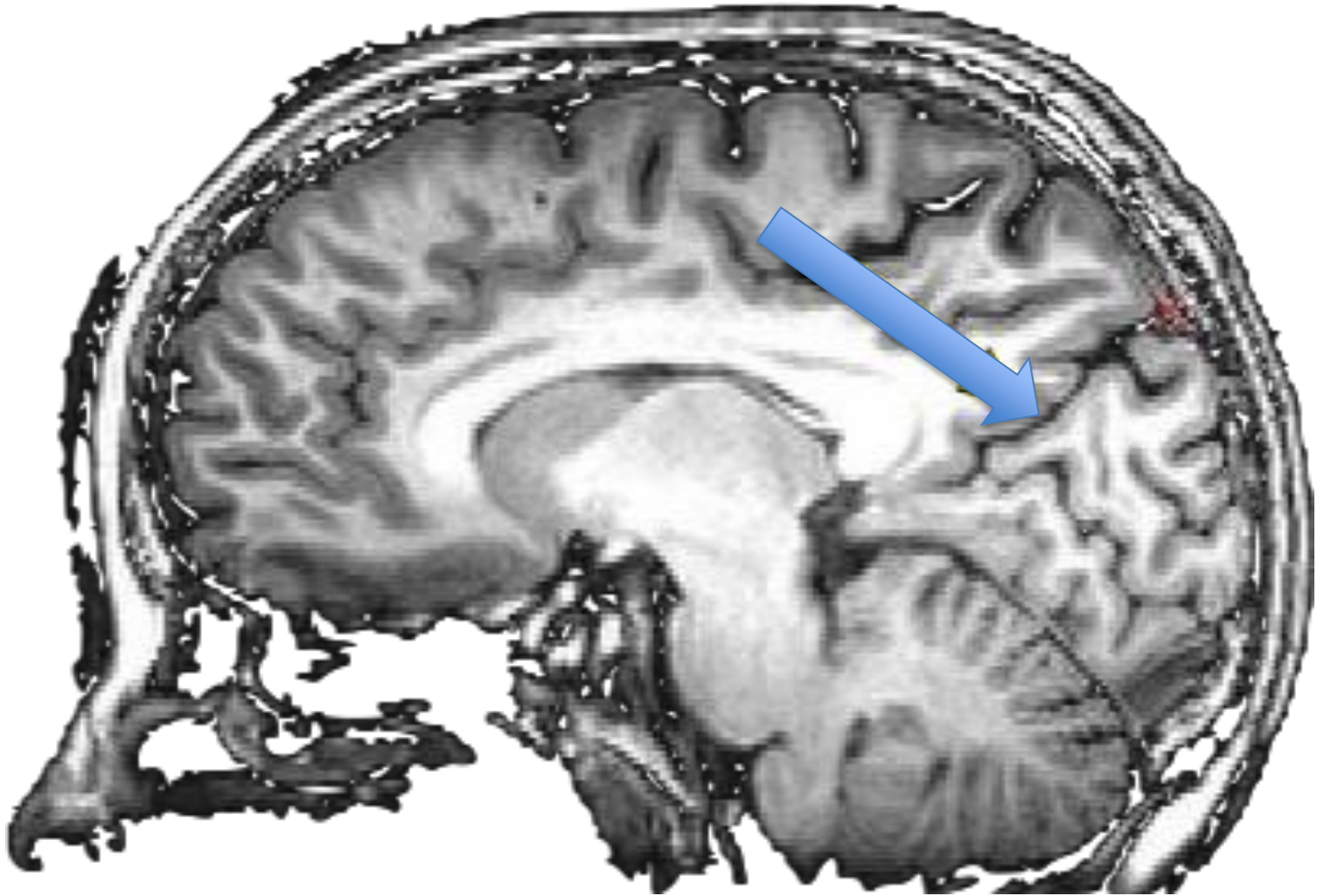
Name this deep grey matter structure



Name this gyrus
(see arrow)



To which white matter structure does the arrow point



To which sulcus does the arrow point on this MRI scan

Answers

1. Gyrus Cinguli
2. Septum pellucidum
3. Nucleus Ruber
4. Thalamus
5. Arteria cerebri media
6. Claustrum
7. Gyrus frontalis medius
8. Corpus callosum
9. Sulcus parieto-occipitalis